

Evaluation of the Protective Role of Pumpkin Seed Oil in Preventing Changes in the Kidney Parenchymal of Rats

Alimova Shakhnoza Azamatovna

Department of Otorhinolaryngology, Bukhara State Medical Institute

alimova.shahnoza@bsmi.uz

Abstract: this article provides information on the results of scientific studies that can assess and study the morphometric indicators of the kidneys of 3-month-old rats who received an energy drink for 90 days and pumpkin seed oil for 30 days.

Key points: kidneys, nephron, Shumlyansky Bowman's capsule, choroid glomerulus.

Abstract: Cardiovascular and especially renal diseases caused by energy drinks are one of the most pressing problems of modern urology and nephrology. However, despite this, the types of energy drinks that have a negative effect on the human body are still increasing. Many of them are now available in more than 140 countries as part of a multi-billion dollar business. [1,2,5].

Today, the rapid development of kidney transplantation in modern nephrology and urology has led to a constant increase in the interest of morphologists in studying the structure of the kidney and its important organ of the urinary system [6,7]. The interest and demand for the study and investigation of the effects of energy drinks, as well as the increase in the incidence of cardiovascular and especially renal diseases of various internal organs, have increased several times [3,4]. Nowadays, among the complications of internal organs that arise as a result of the constant consumption of energy drinks, complications in the kidneys are of particular interest, and the issue of measures aimed at early diagnosis, treatment, and reduction of mortality remains relevant, which requires a deeper study of this problem.

Materials and methods: The study was conducted on 23 white non-breeding rats of both sexes. The rats were kept in standard metal cages (5 rats per cage) with a moderate temperature ($24\pm 20^{\circ}\text{C}$) under normal vivarium conditions. They were kept in quarantine for a week, and after the experimental rats were excluded from somatic or infectious diseases, they were transferred to normal vivarium conditions. During the experiment, the behavior and physiological state of the rats in the standard and experimental groups were monitored. A group of three-month-old animals was formed to determine the morphometric parameters of the kidney structure in postnatal ontogenesis. The rats were given the Gorilla energy drink at a dose of 10 mg/kg, equivalent to 7.5 ml/kg, once a day for 90 days, and pumpkin seed oil at a dose of 2.5 ml/kg once a day for 30 days. The indicated volume was calculated so that the volume of energy drink that each person consumes in one day corresponds to the indicators, according to the results of the average statistical analysis. A standard metal tube was used in order to accurately control the amount of energy drink administered to experimental animals.

For the purpose of morphometric studies, the kidneys were fixed in 10% neutralized formalin, washed in running water for 2-4 hours, then dehydrated in alcohols of increasing concentration and chloroform, and paraffin blocks were prepared from them according to generally accepted methods. Paraffin blocks were cut into 5-8 μm thick sections and stained with hematoxylin and eosin. The prepared histological preparations were examined under 10, 20, 40 objective lenses of a light

microscope. Mathematical processing of the morphological data obtained during the study was carried out on a personal computer using the capabilities of the "STTGRAPH 5.1" program directly from the general matrix of the Microsoft Office data package "Excel 7.0", the standard deviation and representative errors were determined.

Research results: The following data were obtained from 3-month-old white rats that received the Gorilla energy drink for 90 days and were corrected with pumpkin seed oil for 30 days: macroscopically, the kidneys of the 3-month-old white rats of the experimental group were reddish-brown bean-shaped paired organs, located opposite the II-III lumbar vertebrae, and were covered with a smooth and shiny fibrous capsule on the outside. Macroscopically, no visible pathological changes were detected. According to the results of the study, the absolute weight of the kidneys was from 785.94 mg to 949.99 mg, average - 890.43 ± 15.58 mg; length - from 16.66 mm to 20.54 mm, average - 18.76 ± 0.36 mm; width - from 6.87 mm to 10.65 mm, average - 8.88 ± 0.33 mm; thickness - from 6.13 mm to 10.51 mm, average - 8.48 ± 0.31 mm; it was determined that the volume of the kidney ranges from 476.25 mm³ to 962.05 mm³, and the average is 750.79 ± 47.49 mm³.

Histologically, the following changes occurred in the morphological and morphometric parameters of the renal cortex of 3-month-old white rats that received the Gorilla energy drink for 90 days and were corrected with pumpkin seed oil for 1 month: the area of the renal corpuscles increased from 2007.55 μm^2 to 2388.23 μm^2 , with an average of 2259.33 ± 36.3 μm^2 ; the area of the vascular bundles increased from 1409.65 μm^2 to 1886.22 μm^2 , with an average of 1580.8 ± 33.01 μm^2 ; the area of the capsule cavity increased from 318.11 μm^2 to 417.42 μm^2 , with an average of 389.37 ± 9.21 μm^2 (Fig. 1).

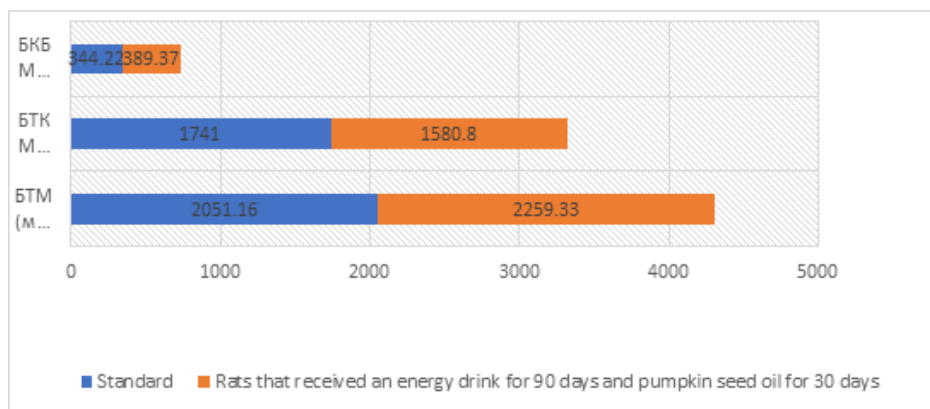


Figure 1. Comparative description of histomorphometric parameters in the kidneys of 3-month-old white rats that received Gorilla energy drink for 90 days and were corrected with pumpkin seed oil for 30 days.

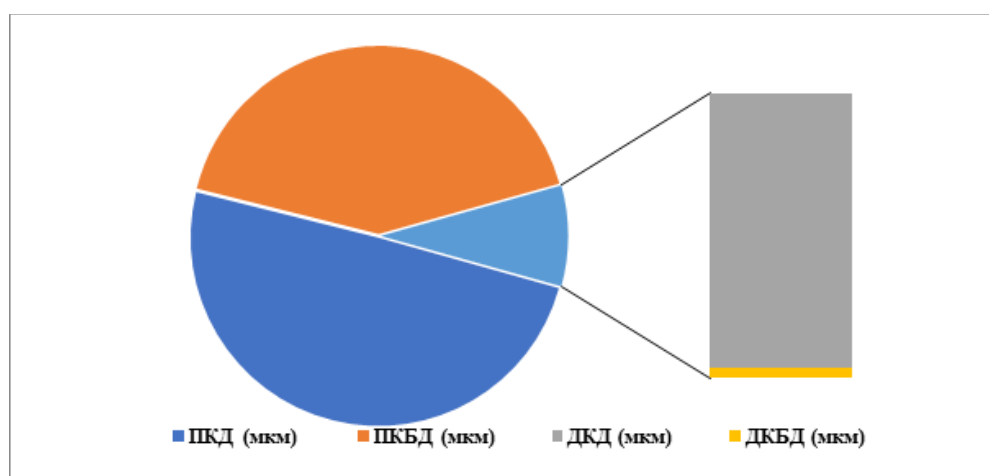


Figure 2. Proximal and distal curvature of the kidneys of 3-month-old white rats that received Gorilla energy drink for 90 days and were corrected with pumpkin seed oil for 30 days каналчаларнинг гистоморфометрик кўрсаткичларининг қийсий тавсифи.

It was noted that the diameter of the proximal convoluted tubules is from 29.11 to 34.84 μm , the average is $32.62 \pm 0.49 \mu\text{m}$, and the diameter of the tubule cavity is from 13.69 to 16.23 μm , the average is $14.97 \pm 0.19 \mu\text{m}$.

The diameter of the distal convoluted tubules is from 23.61 to 28.98 μm , on average - $26.54 \pm 0.45 \mu\text{m}$, and the diameter of their cavity is from 12.33 to 14.87 μm , on average - $13.3 \pm 0.21 \mu\text{m}$ (Fig. 2).

Conclusion: Thus, when 3-month-old rats were given an energy drink for 90 days and pumpkin seed oil for 1 month, the parameters of renal nephron structures were increased by 10.1%, 3.2%, 13.1%, and the proximal curvature of the kidney nephron structures compared to the 1st control group. the average diameter of calcareous tubules and their spaces are 4.6% and 3.1% smaller, the average diameter of distal convoluted tubules and their cavity are 2.9% and 3.6% smaller, which shows that the rats of this group have preserved pathomorphological signs.

LIST OF REFERENCES

1. Бахронов Ж.Ж. Сурункали нур касаллигида буйраклар морфометрик кўрсаткичларининг қиёсий тавсифи ва постнатал онтогенезда биостимуляторлар таъсиридаги ўзгаришлар // 2020 й.
2. Билич Г.Л., Зигалова Е.Ю. Анатомия человека. Русско-латинский атлас. Издательство «Эксмо» ООО 2-издание, -2018. - С. 453-454.
3. Веревкин А.А., Даниленко К.А., Каде А.Х., Накохов Р.З., Саатчян Н.П., Губарева Е.А., Кислица Т.С., Занин С.А. СОСТОЯНИЕ СИСТЕМЫ ПРО-/АНТИОКСИДАНТЫ В КРОВИ КРЫС С МОДЕЛЮ АЛКОГОЛЬНОЙ ЗАВИСИМОСТИ. Современные проблемы науки и образования. 2014. №3
4. Mcgraw MM. Are energy drinks safe? Nursing (Lond). 2013;43(3):68. 9. Shimada S, Hirose T, Takahashi C, Sato E, Kinugasa S, Ohsaki Y, et al. Pathophysiological and molecular mechanisms involved in renal congestion in a novel rat model. Sci Rep. 2018;8(1):1–15.
5. Ardabili A.G., Farhoosh R., Khodaparast M.H. Chemical Composition and Physicochemical Properties of Pumpkin Seeds (*Cucurbita pepo* Subsp. *pepo* Var. *Styriaca*) Grown in Iran. J. Agr. Sci. Tech. (2011) Vol. 13: 1053-1063.
6. Хусейнова, Г. Х., & Тешаев, Ш. Ж. (2020). Сравнительная характеристика морфометрических параметров почек при различных фазах черепно-мозговой инфекции. Новый день в медицине, (2/1), 30.
7. Ш. А. Алимова (2022). Морфометрические изменения в развитии микрососудов анального канала и спинктерного аппарата прямой кишки у крыс на разных этапах постнатального онтогенеза. Scientific progress, 3 (4), 52-56.