

INDIRECT EFFECTS OF CHLORPYRIFOS ON THE HYPOTHALAMIC-PITUITARY NEUROSECRETORY SYSTEM OF RAT OFFSPRING

Dzhumaniyazov Shavkat Atanazarovich

Samarkand State Medical University, Department of Physiology.

Abstract. *The results of the effect of the organophosphorus pesticide chlorpyrifos on the hypothalamic-pituitary neurosecretory system of rat offspring, in case of poisoning during pregnancy and lactation, are presented. In all series of experiments, dose-dependent changes in the HPA axis of the offspring were observed, characterized by inhibition or some activation of the development and functioning of this system.*

Keywords: *hypothalamic-pituitary neurosecretory system, paraventricular nucleus, ontogenesis, supraoptic nucleus, organophosphorus pesticides.*

Introduction. The role of the neuroendocrine system in maintaining homeostasis, in ensuring adaptation processes and compensation for impaired body functions is considered indisputable [1, 2, 3, 15, 16, 17, 19]. Recently, researchers have been particularly interested in studying the neuroendocrine system in the ontogenetic sense, especially in early ontogenesis, when the formation of the structure and function of many organs is not complete, and the system itself is subject to the influence of numerous external and internal factors.

Purpose of the study: study of the mechanisms of morphofunctional changes and the characteristics of the formation of the HPA axis in the offspring of animals exposed to the organophosphorus drug chlorpyrifos.

Materials and methods: The study was conducted on outbred white rats weighing 180-200 g and their offspring at different periods of postnatal development. The animals were divided into 2 groups. The first group consisted of intact animals. In groups 2 and 3, rats were poisoned with chlorpyrifos throughout the entire pregnancy period at a dose of 1/50 and 1/100 LD₅₀, respectively. In groups 4 and 5, rats were poisoned with chlorpyrifos in the 2nd half of pregnancy and during lactation at a dose of 1/50 and 1/100 LD₅₀, respectively. Animals were slaughtered on days 1, 7, 14, 21, and 30 after birth. Pieces of the brain, including the hypothalamus with the pituitary gland, were fixed in Bouen's fluid or according to Carnua. After being passed through alcohols, the pieces were embedded in paraffin, and then 5-7 μm thick sections were prepared from them. The sections were stained using one of the following methods: 1) Nissl cresyl violet; 2) Gomori-Gabe paraldehyde-fuksin (PAF); 3) chromium-gematoxylin. The hypothalamic-pituitary neurosecretory system was studied at the level of the hypothalamic nuclei (SON and PVN), median eminence, and posterior pituitary gland. Changes in the morphofunctional state of neurosecretory cells (NSC) of the supraoptic and paraventricular nuclei were determined by calculating the percentage of individual types of neurosecretory cells [18]. Along with this, the content of neurosecretion in the hypothalamic-pituitary tract and in the posterior part of the neurohypophysis (PPN) was taken into account.

Research results. The most significant destructive changes in the hypothalamic-neurohypophyseal system were observed in the offspring of animals that were poisoned with chlorpyrifos during the entire pregnancy period (in the 2nd and 3rd series of experiments), especially when chlorpyrifos was used at a dose of $1/50$ LD₅₀ (Fig. 1). The most pronounced pathological changes in the form of disorganization and suppression of neurosecretory processes, circulatory disorders and increased neuronal death were observed in fetuses and newborn rats. These observations confirm the position that the most vulnerable are those organs and systems that are at the stage of formation of their structure and function.

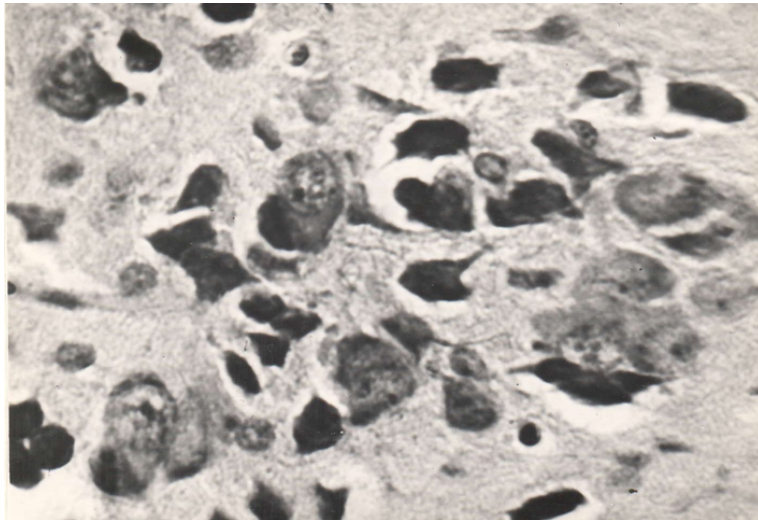


Fig. 1 Numerous destructive neurons with decay of their nuclei. PVN of a 7-day-old rat in case of poisoning at a dose of $1/50$ LD₅₀.

At the same time, cessation of poisoning does not lead to complete restoration of the morphofunctional state of the HPA axis in rats in the first month of life. They continue to show pronounced growth retardation and development of neurons in the large-cell nuclei of the hypothalamus, and 21- and 30-day-old rats demonstrate signs of intense functioning of the HPA axis with signs of exhaustion of compensatory mechanisms.

In addition to the disturbances in the hypothalamic-pituitary system in the rats of this experimental group, we noted a high pre- and postnatal mortality, phenomena of general hypotrophy and a later emergence of the rats. It is likely that the processes of destruction and disintegration of the HPA axis in the rats played a significant role in these phenomena.

A somewhat different picture is observed when studying the ontogenesis of the neuroendocrine system of rat pups exposed to the pesticide chlorpyrifos in the second half of the intrauterine period and continuing to receive this pesticide with mother's milk (the 4th and 5th series of experiments). Thus, in the 4th series of experiments, where pregnant and lactating female rats received chlorpyrifos at a dose equal to $1/50$ LD₅₀, along with destructive changes in the large-cell nuclei of the hypothalamus in newborn rats, signs of active neuronal activity are also observed. In newborn rats of this group, multidirectional reactions of the neurosecretory nuclei of the hypothalamus are noted. If in the SOY there is inhibition of growth and development of neurons, then in the PVN there is active cell growth, accelerated removal of neurosecretion from neurocytes. Continuing poisoning of lactating rats causes an increase in the processes of destruction and dystrophy in both studied nuclei in 7-day-old rats. By the end of the second week of postnatal life, the rat pups still show

signs of growth retardation and development of the hypothalamic-neurohypophyseal system as a whole. Just as in the previous groups of experiments, in 21- and 30-day-old rat pups, we observed a picture of a more active morphofunctional state of the neuroendocrine system compared to the control, with signs of depletion of reserve capacity by the 30th day of postnatal life.

In case of poisoning of female rats with a lower dose of chlorpyrifos (1/100 LD₅₀)

- The 5th series of experiments showed a more pronounced activation of growth and synthetic activity of large-cell hypothalamic neurons in fetuses and newborn rats than in cases of poisoning with chlorpyrifos at a dose of 1/50 LD₅₀ (the 4th series of experiments). At the same time, destructive changes in the neurosecretory nuclei were less pronounced when using a lower dose of chlorpyrifos. Just as when using a higher dose of the pesticide, we observed a slowdown in the growth of neurons and synthetic processes in them in 7-day-old rats, which was more pronounced in SON. But, unlike the rats of the previous group, by the end of the second week of postnatal development, the morphometric parameters of the rats of this experimental group approached the parameters of intact animals, which indicates less damage to the large-cell hypothalamic structures when poisoned with a chlorpyrifos dose of 1/100 LD₅₀. In 21- and 30-day-old rats, as in other experimental groups, we noted a picture indicating high functional activity of neurosecretory cells. At the same time, the analysis of the percentage ratio of different types of neurons does not show an increase in the cellular elements of types III and IV, characteristic of all the above-considered experimental groups of animals and indicating the depletion of the reserve capacity of the studied large-cell nuclei of the hypothalamus. In 30-day-old rats, a pronounced disintegration of the neuroendocrine system is observed, which is manifested in high functional activity of the supraoptic nucleus and moderate - paraventricular, with a parallel delay in the removal of neurosecretory substance from the neurohypophysis. This indicates an excess synthesis of neurohormones induced by the pesticide chlorpyrifos over the real needs for them [4, 5, 6, 7, 10].

Conclusion. Analyzing the possible causes of changes observed in the HPA axis of the offspring of rats poisoned with small doses (1/100 LD₅₀) of chlorpyrifos, we draw attention to the following factors that may underlie the pathogenetic mechanisms of disruption of the morphofunctional state of this system:

- 1) direct effect of the pesticide chlorpyrifos on the cholinergic systems of the hypothalamus;
- 2) disruption of the formation of the neuroendocrine system of the offspring under the influence of the perverted hormonal status of poisoned females;
- 3) violation of the qualitative and quantitative composition of breast milk;
- 4) a combination of the above factors.

REFERENCES

1. **Гудошников В.И.** Роль белков и гормонов стресса в биорегуляции онтогенеза. Проблемы эндокринологии, 2015. 4. С.49-53
2. **Джуманиязов Ш.А.** Карабаев А.Г. Становление функций гипоталамо-гипофизарной нейросекреторной системы в онтогенезе лабораторных крыс.// Проблемы биологии и медицины. 2022, 139 (№5), 266-270

3. **Джуманиязов Ш. А.** Задержка постнатального роста и развития потомства крыс, вызванные химическим стрессом у матери //Scientific approach to the modern education system. – 2023. – Т. 1. – №. 3.
4. **Джуманиязов Ш. А.** Гипоталамо-гипофизарная нейросекреторная система у потомства животных, отравленных хлорпирифосом в течение беременности //Scientific approach to the modern education system. – 2023. – т. 1. – №. 3.
5. **Джуманиязов, Ш. А.,** Карабаев А. Г., Ким Д. В.. "Изучение развития и становления нейросекреторной функции гипоталамо-гипофизарной нейросекреторной системы у плодов и потомства животных, отравленных хлорпирифосом в течение беременности. // Журнал Вестник врача.-2022,- № 3 (106), 2022, стр. 46-51.
6. **Джуманиязов, Ш. А.** (2023). Гипоталамо-гипофизарная нейросекреторная система у потомства животных, отравленных хлорпирифосом в течение беременности. Scientific approach to the modern education system, 1(3).
7. **Джуманиязов, Ш. А.** (2023). Задержка постнатального роста и развития потомства крыс, вызванные химическим стрессом у матери. Scientific approach to the modern education system, 1(3).
8. **Джуманиязов Ш. А.** Гипоталамо-гипофизарная нейросекреторная система у потомства животных, при интоксикации хлорпирифосом в период беременности. // Сборник материалов 77-й Международной научно-практической конференции «Достижения фундаментальной, прикладной медицины и фармации». Самарканд – 2023, стр. 91
9. **Джуманиязов Ш. А.** Задержка роста и развития потомства крыс, вызванные химическим стрессом у матери. // Сборник материалов 77-й Международной научно-практической конференции «Достижения фундаментальной, прикладной медицины и фармации». Самарканд – 2023, стр. 91-92.
10. **Джуманиязов Ш.А.,** Нуримов П.Б. Гипоталамо-гипофизарная нейросекреторная система у потомства крыс, при воздействии фосфорорганических пестицидов. Ethiopian International Multidis-ciplinary Research Conferences. Vol. 2 No. 1 (2023) pp. 3-6
11. **Джуманиязов Ш.А.,** Карабаев А.Г. Гипоталамо-гипофизарная нейросекреторная система у потомства крыс, при воздействии ФОС хлорпирифос на организм матери. Материалы XXXIV Всероссийской научно-практической конференции с международным участием. 2023. Казань. стр. 38-41
12. **Джуманиязов Ш. А.** (2024). Нарушение постнатального роста и развития потомства крыс, вызванные химическим стрессом у матери. Биология и интегративная медицина, (3 (68)), 275-281.
13. **Джуманиязов Ш.А.** Лаборатория каламушларининг онтогенезида гипоталамо-гипофизар нейросекретор тизимнинг шаклланиши. //Тиббиётда янги кун / Новый день в медицине 2024. 66 (4), 394-398
14. **Atanazarovich, D. S., & Gadaevich, K. A.** (2022). Hypothalamic-Pituitary Neurosecretory System in Fetuses and Offspring of Animals Poisoned with Chlorpyrifos During Pregnancy. Central Asian Journal of Medical and Natural Science, 3(6), 274-280.
15. **Djumaniyazov Sh. A.,** Kuldashev SH. I. Neuroendocrine System And Toxic Environmental Factors //Internat. J. of Medical Sciences. -2024; 4 (04), 76-80
16. **Djumaniyazov Sh. A.** Delay of Postnatal Growth and Development of Rat Offspring Caused by Mother's Chemical Stress // American Journal of Medicine and Medical Sciences. 2024; 14(6): 1670-1672

17. **Карабаев А. Г.** Патогенетические основы нарушения морфофункциональной активности нейросекреторных клеток аркуатного ядра гипоталамуса в постреанимационном периоде. «Тиббиетда янги кун» 3 (35) 2021. 137-142.
18. **Поленов А.Л., Константинова М.С., Гарлов П.Е.** Гипоталамо-гипофизарный нейроэндокринный комплекс // Нейроэндокринология. СПб., 1994. т.2.- с. 139-286.